

Post- versus intra-operative implant for breast cancer interstitial brachytherapy: How to choose?

Marta Gimeno-Morales, MD, PhD^{1*}, Laura Motisi, MD^{2*}, Natalia Rodriguez-Spiteri, MD, PhD³, Fernando Martínez-Regueira, MD, PhD³, Tucker Worthington, Radiation Therapist², Vratislav Strnad, MD, PhD⁴, Jean Michel Hannoun-Levi, MD, PhD⁵, Cristina Gutierrez, MD, PhD⁶

On behalf of Working Group Breast Cancer of GEC ESTRO

¹Department of Radiation Oncology, Cancer Center Clinica Universidad de Navarra, Pamplona, Spain, ²Department of Radiation Oncology, Zürich University Hospital, Zürich, Switzerland, ³Department of Breast Surgical Oncology, Cancer Center Clinica Universidad de Navarra, Pamplona, Spain, ⁴Department of Radiation Oncology, Erlangen University Hospital, Erlangen, Germany, ⁵Department of Radiation Oncology, Antoine Lacassagne Cancer Centre, University of Côte d'Azur, Nice, France, ⁶Department of Radiation Oncology, Institut Català d'Oncologia, Barcelona, Spain

*Marta Gimeno-Morales and Laura Motisi contributed equally in this work.

Abstract

Purpose: Breast brachytherapy (BB) represents an important radiation therapy modality in modern breast cancer treatments. Currently, BB is mainly used for accelerated partial breast irradiation (APBI), local boost after whole breast radiation therapy (WBRT), and as salvage re-irradiation after second lumpectomy (APBrI). Two multi-catheter interstitial brachytherapy (MIB) techniques can be offered: intra-operative (IOB) and post-operative (POB) brachytherapy. The aim of this article was to summarize current available data on these two different brachytherapy approaches for breast cancer.

Material and methods: A literature search was performed, and different experiences published by BB expert teams were analyzed and compared. These two different brachytherapy approaches for breast cancer have also been presented and discussed during meetings of the GEC-ESTRO BCWG. In addition, expert recommendations were defined.

Results: A comprehensive description and practical comparison of both the techniques, i.e., IOB and POB, considering the latest available published data were presented. Different technical, logistic, and clinical aspects of both the methods were thoroughly examined and analyzed. This detailed comparison of the two breast brachytherapy techniques was supported by scientific data from extensive experience of experts, facilitating an objective analysis that, to our knowledge, has not been previously published.

Conclusions: Based on the comprehensive analysis of both the brachytherapy techniques available, this article serves as a valuable resource to guide breast teams in selecting the optimal BB technique (POB or IOB), considering hospital environment, multi-disciplinary collaboration, and patient logistics.

J Contemp Brachytherapy 2024; 16, 1: 72-83

DOI: <https://doi.org/10.5114/jcb.2024.135635>

Key words: breast cancer, brachytherapy, accelerated partial breast irradiation, intra-operative brachytherapy, post-operative brachytherapy.

Purpose

Breast conserving surgery (BCS), followed by radiation therapy, is crucial in reducing local recurrence risk for breast cancer patients. This is applicable not only for primary tumors, but also for cases of recurrence after a second conservative treatment [1, 2]. Breast brachytherapy, encompassing accelerated partial breast irradiation (APBI) [3] or as a boost after whole breast radiation therapy (WBRT) [4-6], has been firmly established for selected patients, as recommended by international guidelines [7-10].

After a second conservative treatment, such as accelerated partial breast re-irradiation (APBrI) [11], it is also offered to patients with an ipsilateral breast tumor recurrence (IBTR) as salvage therapy.

Multi-catheter interstitial breast brachytherapy (MIB) emerges as a versatile radiation technique due to its ability to confine the irradiated target volume, thereby reducing organs at risk exposure, minimizing complications, and enhancing cosmetic outcomes [12, 13]. Furthermore, MIB offers a reduction in treatment logistics, typically

Address for correspondence: Marta Gimeno-Morales, MD, PhD, Department of Radiation Oncology, Cancer Center Clínica Universidad de Navarra, University of Navarra, Avenida de Pío XII, 36, 31008 Pamplona, Spain, phone: +34-948-255-400, e-mail: mgmorales@unav.es

Received: 05.12.2023

Accepted: 20.01.2024

Published: 23.02.2024

completed in under 5 days, in the era of normo-fractionation or hypofractionation. Thus, it updates patient logistics [14-17].

The MIB technique is tailored to BCS and brachytherapy timing. There are two distinct methods. The first is post-operative implant procedure, which is followed by a post-operative brachytherapy (POB). The second employs an intra-operative implant procedure, followed by a peri-operative brachytherapy (IOB). This manuscript meticulously analyzed both the techniques, exploring technical, clinical, patient, and logistical nuances from the most relevant published data and expert criteria [3, 18-27]. Through this comprehensive evaluation, breast surgeons and radiation oncologists can gain insights to choose the most suitable procedure for implementation in their clinical practice.

Material and methods

A comprehensive scientific review faced limitations due to the absence of technical aspects referenced in key words or abstract descriptions. These limitations were overcome by selectively extracting relevant series from expert teams in breast brachytherapy. Our analysis focused on comparing experiences of both multi-catheter interstitial breast brachytherapy (MIB) techniques. Additionally, insights from GEC-ESTRO BCWG meetings and expert recommendations enriched our study.

Surgical consideration of breast conserving surgery technique for multi-catheter breast implant

Candidates for MIB primarily target those with small tumors undergoing BCS. APBI with POB ensures excellent oncologic outcomes and cosmetic results [21].

Long-term cosmesis relies heavily on surgical criteria and technique, regardless of radiation technique used. Essential surgical criteria, involving minimal specimen size and discreet incisions (periareolar, axillary, sub-mammary, or lateral chest) to avoid volume depletion or poor cosmesis, are recommended to achieve the optimal cosmesis outcomes [28]. This “scarless” surgery allows a wide subcutaneous dissection over a tumor lo-

cation and local reconstruction with adjacent breast tissue, which is a very suitable surgical technique for MIB. Unlike other intra-operative radiation techniques, such as intra-operative electron radiotherapy technique (IOERT), MIB adapts to incisions, avoiding extensive scars. Additionally, oncoplastic surgical techniques are not a contraindication for MIB [29]. Whenever the tumor target area is easily identified by breast surgeon and radiation oncologist, together, they can delineate the correct area to implant.

Intra-operative sentinel node biopsy, conducted through the same incision, minimizes scarring [30] and provides crucial information for APBI patients, especially in case of IOB MIB technique. Furthermore, intra-operative pathology analysis of margin status addresses the need for further breast tissue resection [31]. The resection margin measurement, in different directions, determine the surgical cavity to be covered by implant. Precise surgical clip placement is also crucial for accurate target definition. If no clips are inserted in place, the area to be targeted cannot be easily and securely identified, and this can contribute to inaccurate target volume delineation [4, 32, 33]. In conclusion, an efficient collaboration between the radiation oncologist and breast surgeon is essential for MIB success.

General aspects of multi-catheter interstitial breast brachytherapy

Regardless of clinical indication, MIB prioritizes optimal coverage of tumor bed and clinical target volume (CTV). The implant procedure begins with a “guide needle” at the tumor bed center, with subsequent needles encircling it on planes to ensure complete coverage. A breast template facilitates parallel and geometric catheter placement, while a template-free or free-hand techniques demand expertise [25]. Adhering to Paris system, catheters are positioned at a parallel distance of 1.2 cm to 1.6 cm across distinct planes. This ensures a uniform dose distribution, minimizes high-dose regions, and facilitates a sharp dose fall-off beyond the irradiated zone to protect organs at risk (OARs) [34, 35]. After implant completion, metallic needles are replaced with plastic catheters (Figure 1D). Single-plane implants are generally

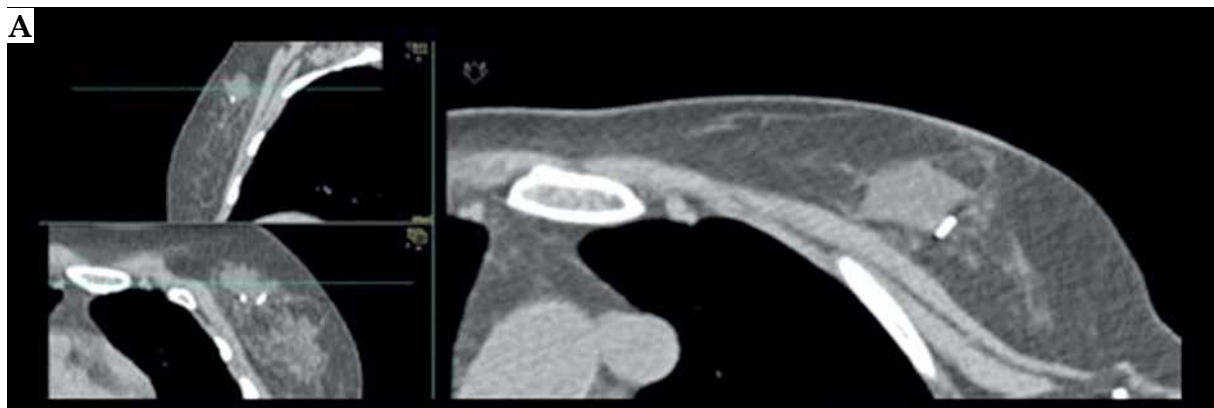

Fig. 1. A case of post-operative brachytherapy (POB) with pre-implant requirements, implant procedure, and dosimetry planning issues. A) Pre-POB CT. The open cavity due to seroma and clips are shown

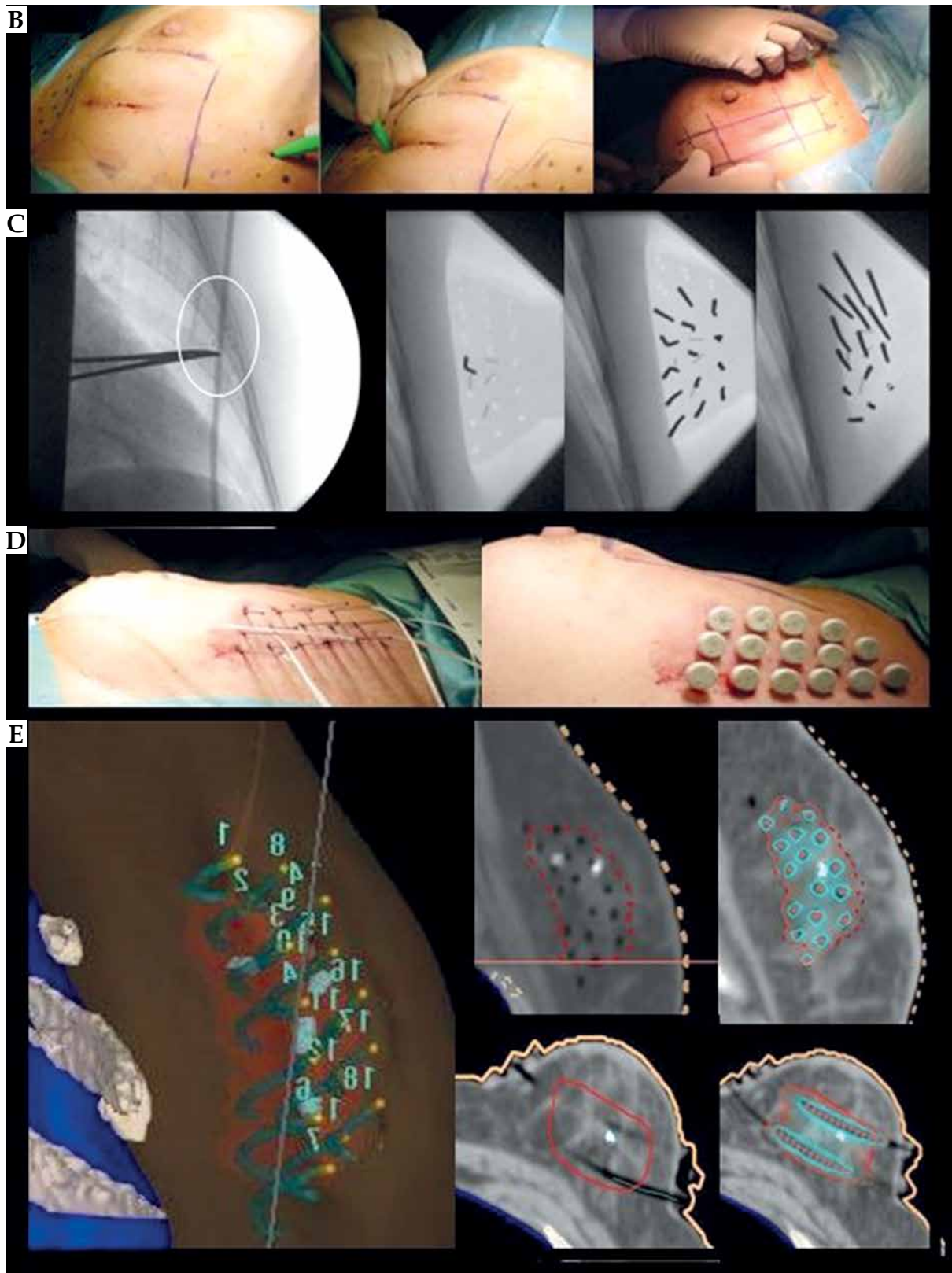


Fig. 1. Cont. **B)** Implant design of implant direction based on scar. **C)** X-ray-guided POB procedure. Verification of surgical clips (white circle) and first needle location with MIB template. Metallic vectors are located around surgical clips based on template. **D)** Metallic vectors are replaced by plastic tubes. **E)** CT planning with CTV, clips, OARs delineation, catheter reconstruction, and isodose distribution

Table 1. Generalities, technical, and clinical aspects of post-operative brachytherapy (POB) and intra-operative brachytherapy (IOB) procedures

General, clinical and technical aspect from MIB (POB & IOB)		Geometrical distribution based on Paris system		
		Stages		
		Pre-implantation	Implantation	Post-implantation
POB	Clinical aspects	<ul style="list-style-type: none"> – Breast examination – Scar healed 		<ul style="list-style-type: none"> – Antibiotic therapy is not mandatory – Painkiller therapy may be required
	Technical aspects	<ul style="list-style-type: none"> – Diagnostic radiology studies, including MRI if possible – Review of surgical report 	<ul style="list-style-type: none"> – Detection of clips to localize target area (X-ray). If no clips, reconstruction of tumor bed with images and reports 	<ul style="list-style-type: none"> – Plan CT to verify needles' correct location, absence of complications, and geometric implant, to achieve uniform dose shape
IOB	Clinical aspects	<ul style="list-style-type: none"> – Measurement of tumor-skin distance according to breast ultrasound – Assure enough breast volume 	<ul style="list-style-type: none"> – Verification of pNO for clinical indication of APBI – No macroscopic evidence of multi-focality at specimen visualization – Margin-free status at macroscopic visualization (CDIS > 5 mm and CDI > 2 mm) 	<ul style="list-style-type: none"> – Pathology results as soon as possible to confirm indication – Antibiotic therapy is not mandatory – Painkiller therapy may be required
	Technical aspects	<ul style="list-style-type: none"> – Diagnostic radiology studies, including MRI if possible – Consensus of surgical approach – Assure enough breast volume 	<ul style="list-style-type: none"> – Surgical closure technique to achieve geometrical implants – Visualization of radiation target – Accurate identification of tumor bed within surgical bed 	<ul style="list-style-type: none"> – Plan CT to verify needles' correct location, absence of complications, and geometric implant, to achieve uniform dose shape

discouraged to prevent dose inhomogeneity. Pre-operatively measured distances exceeding 10 mm between the tumor and skin prevent skin hyperpigmentation. Special consideration is crucial for deep implants near the chest wall to mitigate risks of neuropathy or costal fractures.

Post-operative multi-catheter breast brachytherapy

Post-operative brachytherapy is performed post-BCS as a separate surgical procedure, after fulfillment of clinical criteria. Technical and clinical aspects are summarized in Table 1, with an illustrative example shown in Figure 1.

Pre-implantation requirement

A pre-implant computed tomography (CT) is conducted a day before brachytherapy. Pre-operative images (mammogram, breast ultrasound, and optional magnetic resonance imaging - MRI), clinical examination, and scar position aid the radiation oncologist in accurately locating the target area. For POB, virtual implantation and planning on pre-implant CT offer crucial guidance for catheter insertion during the procedure. This step enhances the orientation of implant [4], and it is pivotal for the POB procedure. Additionally, it allows for the creation of individualized 3D printing breast templates [36, 37].

Implantation requirements

The POB implant procedure is performed under either local or general anesthesia. Catheters are inserted

transcutaneously, *via* a template-based system, and guided by intra-procedure breast ultrasound or X-ray control to ensure accuracy and visualization of tumor bed clips (Figure 1C). Comprehensive procedural general insights are provided by the GEC-ESTRO guidelines [4].

Organizational aspect

Post-operative brachytherapy should be ideally conducted within 12 weeks after BCS, or at most, 4 weeks after the completion of adjuvant chemotherapy. Non-radiotherapy hospitals are encouraged to facilitate patient referral to specialized breast brachytherapy centers. Figure 2 shows the workflow of organizational process for POB.

Intra-operative multi-catheter breast brachytherapy

After tumor and sentinel node removal, IOB takes place concurrently with BCS, requiring coordinated efforts of radiation oncologists, breast surgeons, and pathologists. Technical and clinical details are outlined in Table 1, with an illustrative example in Figure 3.

Pre-implantation requirements

Pre-operative images (mammogram, breast ultrasound, and optional breast MRI) offer crucial insights into tumor characteristics (location, size, tumor-skin distance, etc.). They assist in the design of suitable breast brachytherapy procedures. For APBI patients, it is important to note a potential 20-25% rate of unsuitability

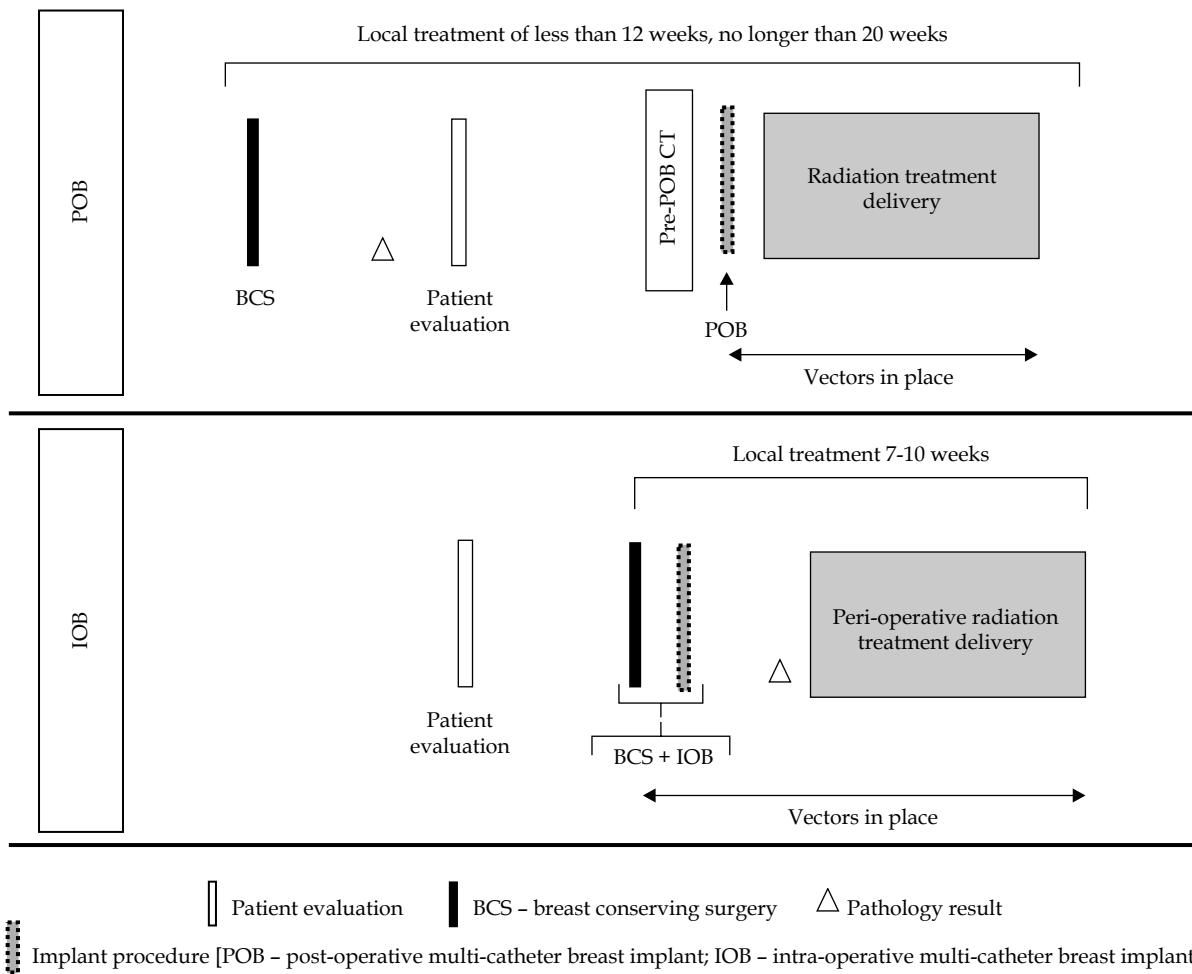


Fig. 2. Post-operative brachytherapy (POB) and intra-operative brachytherapy (IOB) flowchart of organizational procedures

after implantation; however, these cases can still benefit from an anticipated boost [25, 38]. While a previous planning CT can be considered [4], its utility is limited due to the visualization of tumor bed during the surgical procedure.

Implantation requirements

Post-tumor resection, with precise marking of the surgical specimen is crucial for subsequent intra-operative frozen section histological examination. Tumor visualization within the specimen, along with measuring

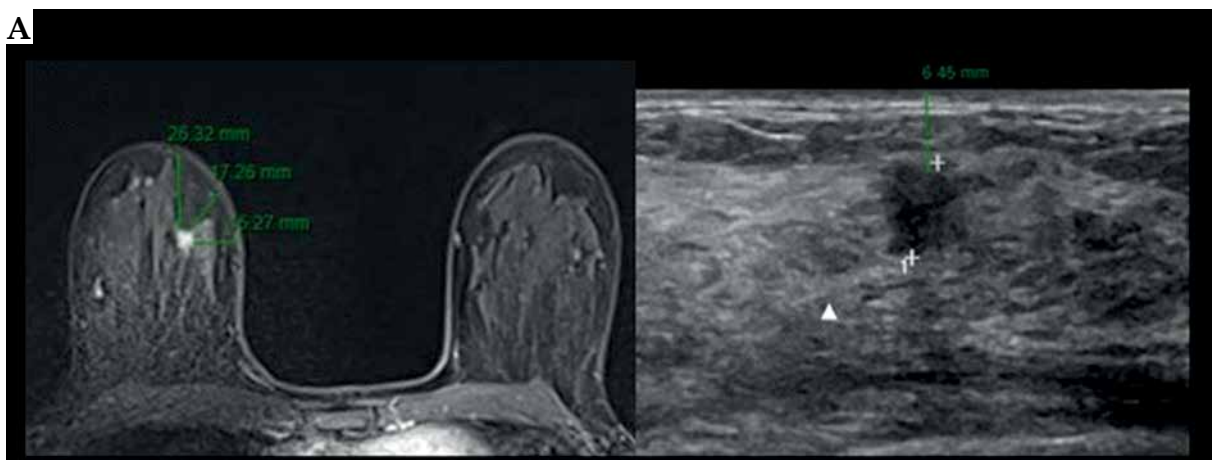


Fig. 3. A case of intra-operative brachytherapy (IOB) with pre-implant requirements, implant procedure, and dosimetry planning issues. A) Breast MRI and breast ultrasound, with measures of tumor-skin distance

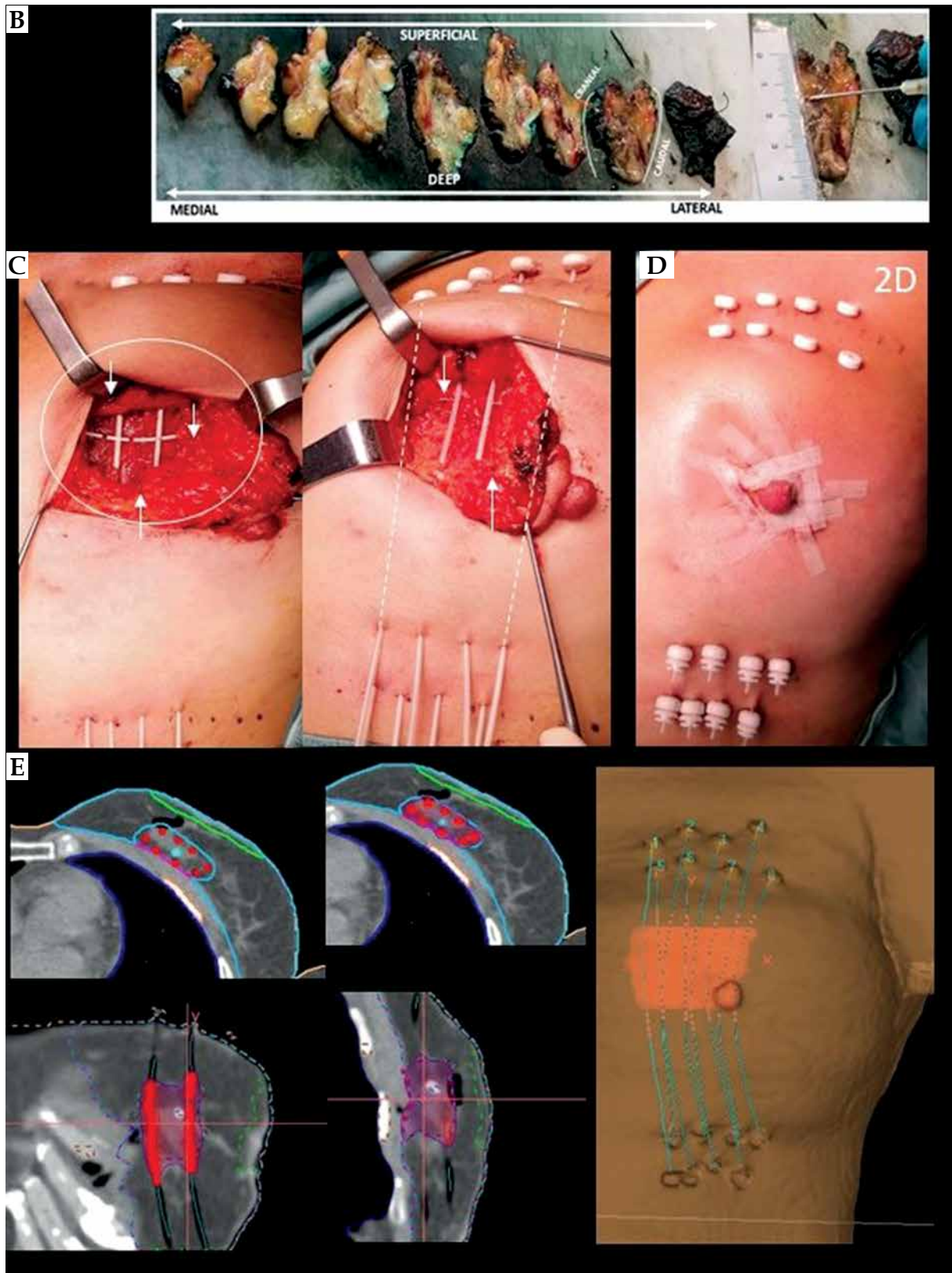


Fig. 3. Cont. **B)** Pathology macroscopic visualization, margin measurement, and tumor location. **C)** Intra-operative design of implant procedure of a patient with a peri-areolar incision. Topographical identification of a high-risk area of tumor bed in surgical cavity (solid white line), with clip references (white arrows). The area to be implanted corresponds to a tumor bed plus a 1-2 cm margin, based on visualization of breast specimen and tumor location with margin relationship. **D)** Final breast conserving surgery with IOB. **E)** CT planning with CTV, clips, OARs delineation, catheter reconstruction, and isodose distribution

of macroscopic margin resection, helps in identifying the high-risk area for implantation (Figure 3B). This information guides the brachytherapist in determining the extent of the implant and adjusting its position in the surgical bed. Once the location and depth are established, clips are placed on the surgical bed to indicate tumor boundaries. The implantation area fully encompasses a 2 cm radius margin around the tumor edges, which incorporates the intra-operative macroscopic margin status provided by the pathologist [32]. This ensures proper future CTV delineation and target irradiation [39] (Figure 3E). To minimize geometric disturbances, maintaining a perpendicular implant orientation to the wound closure is recommended. Finally, a drainage system may be retained to prevent seroma, hematoma, or air in CTV, typically removed 24-48 hours after BCS.

Organizational aspect

Local treatment, including surgery and peri-operative adjuvant irradiation, is completed within 7-10 days to confirm the indication (APBI, boost, or APBrI). This is based on definitive pathology results, expected within 48 hours post-BCS. Figure 2 illustrates the workflow of organizational process for POB.

General aspects of planning and treatment delivery

Historically, brachytherapy dose prescriptions relied on reference points, and 2D dose distribution planning was guided by catheter geometries. Modern practice follows 3D image-guided brachytherapy as the gold standard. It incorporates CT images for delineation, planning, and dose calculation. Inverse dose planning and DVH evaluation enhance dose distribution conformity, accuracy, reproducibility, and quality for MIB [34]. Post-implant CT scan validation ensures the accuracy of catheter insertions and implant geometry. The 3D image-guided brachytherapy planning begins with reconstructing catheters and delineating CTV and organs at risk [4] (Figures 1E and 2E).

For CTV delineation, the GEC-ESTRO guidelines determined the process for POB [32, 33]. For IOB, the contour of CTV corresponds to the catheter-based area implanted [39]. Surgeon collaboration can verify clip position. In both the MIB techniques, additional post-implantation needles may enhance coverage.

Second, the prescription dose must cover 90% of CTV, assuring a proper dose homogeneity index (DHI) value. Physicists and radiation oncologists optimize dose delivery for a homogenous dose distribution, following guidelines [4].

Thirdly, once the plan is ready, the treatment begins with implant connection to afterloading machine, typically with high-dose-rate (HDR) sources, such as iridium-192, although PDR can also be used. This procedure takes a few minutes and is repeated 1 to 10 times, depending on the prescribed schedule, at intervals of at least 6 hours. Hospitalization is generally unnecessary. Antibiotic prophylaxis is at the physician discretion, and particularly recommended in IOB. Different protocols

can be considered, adapted to each hospital or healthcare system's patient workflow.

Discussion

Two different MIB techniques are available: POB and IOB. Nevertheless, comprehensive phase III trials comparing POB and IOB remain absent, and retrospective comparative investigations are also lacking. The most relevant studies are summarized in Table 2. In the subsequent sections, we meticulously analyzed both the techniques, exploring dosimetric nuances, clinical outcomes, safety profiles, and toxicities. This analysis incorporated the perspectives of surgeons, radiation oncologists, and patients.

POB vs. IOB: Technical and dosimetry considerations

Post-operative brachytherapy and IOB share comparable technical aspects, but nuanced differences deserve emphasis regarding target volume accuracy, number of catheters used, and CTV volume delineation. The real-time nature of IOB provides certainty in target identification accuracy [25, 39]. Moreover, IOB series report a lower number of inserted catheters, covering the tumor bed, pioneering the concept of minimally invasive tumor bed implants [38]. In terms of target delineation, POB is based on cavity type (opened or closed) [29, 30], adhering to the published guidelines for consistent criteria. For IOB, a secure CTV delineation approach is the catheter-based methodology advocated by Sato *et al.* [39]. This has resulted in smaller irradiated volumes in IOB series, reporting median CTV volumes of approximately 30-44 cc, equivalent to 4-5% of breast tissue irradiation [15, 17, 40]. This contrasts with a 81 cc of CTV (range, 7-275 cc) in the GEC-ESTRO phase III trial [3], or a 63 cc (range, 27-120 cc) in the Budapest trial [41] using POB. Additionally, patients with small breasts, where single-plane implantation is mandatory and CTV is therefore reduced, were not recognized as a risk factor for ipsilateral breast tumor recurrence (IBTR), with a 4-year IBTR-free survival of 97.5% [42]. CTV volumes and OARs doses significantly surpass those observed in other radiation techniques, such as IMRT-APBI or CyberKnife [43-45].

While a dosimetric analysis comparing CTV volumes and other dosimetry parameters between POB and IOB has not yet been published, early-term clinical and toxicity outcomes do not reveal substantial and obvious differences. A recent multi-center study reported initial analysis showing that POB and IOB provide equivalent dosimetric and early-term clinical (oncological and toxicity) results, presented at the ASTRO 2023 meeting [19]. See Table 2 and the examples provided in Figures 1 and 3.

POB vs. IOB: Clinical outcome considerations

Pivotal phase III APBI trials, including the Budapest, GEC-ESTRO, and NSABP B-39/ RTOG 0413 trials, have comprehensively validated MIB for APBI. These trials primarily focused on the POB approach, highlighting its safety and efficacy with more than a decade of case fol-

Table 2. Interstitial breast brachytherapy implant relevant studies for post-operative brachytherapy (POB) and intra-operative brachytherapy (IOB)

Author, year [Ref.] Technique (POB/IOB)	Number of patients (n)	Median follow-up (years) (range)	Early complications rates	Local recurrences (%) (95% CI)	General outcomes OS, DFS, SCC (%)	Toxicity
Arthur <i>et al.</i> , 2008 [18] POB	99	7.0	1 pt. pneumothorax 12 pts. infection 1 pt. wound dehiscence 1 pt. bleeding	4.0	5-y OS, 93.0 5-y DFS, 87.0	Acute: G1 (82%), G2 (57%), G3 (3%), G4 (9%) Late: G3 (HDR, 2%; LDR, 9%)
Vicini <i>et al.</i> , 2019 [46] POB (27%)	4,216 (APBI, 2,107)	10.2	Not reported	3.9	10-y OS, 90.6 10-y DFS 78.1	Late: G1 (40%), G2 (44%), G3 (10%), G4-5 (< 1%)
Polgár <i>et al.</i> , 2020 [41] POB	128	17.0	1 pt. acute skin adverse effect (6 fx. received instead of 7)	20-y, 9.6	20-y DFS, 79.7 20-y OS, 59.5	Worse toxicity profile in treated volume from 175 to 330 cm ³ , no further information
Strnad <i>et al.</i> , 2016 [3] POB	274	63.0 mts.	Not reported	5-y IBTR, 2.9	5-y OS, 97.0 5-y DFS, 96.0	Acute: G1-2 skin (6.57%), infection (3.28%), hematoma (2.19%) Late: G1 hyperpigmentation (1.8%), fat necrosis (5.1%), G1-2 telangiectasia (17.2%), G1-2 fibrosis (16.1% and 13.9%), G3 fibrosis (0.4%)
Strnad <i>et al.</i> , 2023 [21, 48] POB	1,328 (APBI, 655)	10.36	Infection (5%), low-grade intra-operative breast injury (5%), mild hematoma (20%) (grade 1, 6%)	10-y LRR, 3.51	10-y DFS, 84.89	Late: G1-2 skin RTOG (11%), G3 (1%), G1-2 subcutaneous (47%), G1-2 breast pain (20%)
Sato <i>et al.</i> , 2013 [60] IOB	157	30.0 mts. (1.7-41 mts.)	Wound breakdown for infection (7.5%)	3 pts. local failure 2 pts. IBTR 1 pts. node recurrence		Acute: G1 (13.2%) G2 (3.1%) Late: Seroma (1.3%), wound breakdown for infection (6.3%)
Cambeiro <i>et al.</i> , 2016 [25] IOB	88	35.5 mts. (8.7-62.4 mts.)	12 in 10 pts. (11.3%)	1 pt. contra-lateral	3-y LRC, 100.0	Acute: G0 (57.9%), G1 (36.4%), G2 (5.6%) Late: G0 (32.1%), G1 (57.1%), G2 (10.7%)
Sato <i>et al.</i> , 2017 [27] IOB	237	50.0 mts. (25.5-83 mts.)	Not reported	4-y IBTR-FS, 98.9	4-y DFS, 97.0 4-y OS, 99.6	Not reported
Hannoun-Lévi <i>et al.</i> , 2018 [17] IOB	26	37.2 mts. (35.6-42.3 mts.)	Not reported	5-y LRFS, 100.0	5-y OS, 100.0 5-y CSS, 95.2	Acute: G1 (75.5%), G2 (22.8%), G3 (4.5%)
Hannoun-Lévi <i>et al.</i> , 2020 [26] IOB	26	63.0 mts. (60-68 mts.)	Not reported	5-y LRFS, 100.0	5-y OS, 88.5 5-y CSS, 100.0	Late: G1 (60%), G2 (40%)
Kinj <i>et al.</i> , 2018 [40] IOB	44	40.0 mts. (36-42 mts.)	Not reported	3-y LRFS, 100.0	3-y SS, 100.0 3-y OS, 93.1	Acute: G1 (26.7%), G2 (0%), G3 (6.3%) Late: G1 (86.7%)
Cozzi <i>et al.</i> , 2018 [24] IOB	59	40.0 mts. (1-136 mts.)	Not reported		3-y OS, 89.0 3-y DFS, 97.0	Acute: Mastitis (1.6%) Late: Fibrosis G3 (5.6%), fibrosis G4 (18.1%), mastitis (5.5%), hypochromia (14.8%), hyperpigmentation (7.4%), telangiectasis (1.9%)

Table 2. Cont.

Author, year [Ref.] Technique (POB/IOB)	Number of patients (n)	Median follow-up (years) (range)	Early complications rates	Local recurrences (%) (95% CI)	General outcomes OS, DFS, SCC (%)	Toxicity
Morales <i>et al.</i> , 2020 [38] IOB	24	100.0 mts. (43-137 mts.)	4 pts. (hemorrhage, 16%; infection or skin necrosis) Late: 1 pt. fat necrosis (8.3%)	LC, 95.8 EC, 95.8 1 pt. true local recurrence (62.2 mts.) 1 pt. elsewhere (103 mts.)	LRC and DC, 100.0	Acute: G0 (45.8%), G1 (45.8%), G2 (8.3%) Late: G0 (58.3%), G1 (25%), G2 (16.6%)
Morales <i>et al.</i> , 2022 [15] IOB	60	27.0 mts. (11-51 mts.)	11% Bleeding: 4 pts. (6.6%) Wound healing: 2 pts. (3.3%) Late: 5.1%	Local control rate, 100.0 Elsewhere control rate, 98.3	Loco-regional and distant-control rates, 100.0	Acute: G0 (88.3%), G1 (11.7%), G2 (0%) Late: G0 (63.3%), G1 (36.7%)

POB – post-operative multi-catheter breast implant, IOB – intra-operative multi-catheter breast implant, OS – overall survival, DFS – disease-free survival, DC – distant control, LC – local control, EC – elsewhere control, IBTR – ipsilateral breast tumor recurrence, IBTR-FS – ipsilateral breast tumor recurrence-free survival, LRR – local recurrence rate, LRFS – loco-regional-free survival

low-up [21, 41, 46]. In contrast, IOB was explored in institutional prospective registered phase I-II studies with shorter follow-ups [24-27, 47].

The Budapest trial reported a 10-year local recurrence (LR) rate of 5.9%, a 10-year disease-free survival (DFS) of 85%, and a 10-year overall survival (OS) of 80% [20]. The GEC-ESTRO group showed a 10-year loco-regional recurrence (LRR) rate of 3.51%, a 10-year DFS of 84.89%, and a 10-year OS of 90.47% [21]. The RTOG 0413 trial revealed a 10-year LC rate of 3.9%, a 10-year DFS of 78.1%, and a 10-year OS of 90.6% for patients undergoing POB [46]. Turning to APBI-IOB, Sato *et al.* reported an IBTRs-FS rate of 98.9% in 237 patients treated after 50 months, along with a remarkable 4-year OS and DFS of 99.6% [47]. Cambeiro *et al.* observed a 100% LC rate for 88 patients, with a median follow-up of 38.4 months [25]. Hannoun-Lévi *et al.* demonstrated the safety of the technique with 26 elderly patients, showing a 5-year LRFS rate of 100% and a 88.5% OS at a 5-year follow-up [26]. Oncological outcomes from IOB studies are presented in Table 2. While the number of patients treated with IOB-APBI is small and long-term oncological outcomes are still pending, no visible differences in oncological outcomes emerge when comparing IOB with POB. Preliminary results from a recent multi-center study presented at the 2023 ASTRO meeting, involving 516 APBI-eligible patients treated with IOB (50.2%) or POB (49.8%), revealed a 4-year cumulative incidence of local and regional recurrence rate of 2% and 1%, respectively, with no statistically significant differences based on the implant procedure [19]. Additional details are provided in Table 2.

POB vs. IOB: Safety and toxicity considerations

The safety of each technique is assessed through complication rates during implantation. POB complications

highlighted in the trials are negligible, and may not be exhaustively reported. The GEC-ESTRO trial reported a 5% rate of infection or low-grade breast injury, but up to 20% rate of mild grade 1 hematoma compared with 2.2% in the WBRT arm [48]. In the RTOG 95-17 study, the following infrequent complications were reported: 1 pneumothorax, 12 infections, 1 wound dehiscence, and 1 case of bleeding in 99 patients treated with POB [46]. Notably, Polgar *et al.*'s extended experience revealed minimal and not clinically relevant early complications for POB [49, 50]. In case of IOB, a rate of around 10% of peri-operative complications was reported, with common issues, including minor bleeding, infection, and wound healing. Hannoun-Lévi *et al.* reported a 9% complication rate [17], while Cambeiro *et al.* documented 11.3% complications, including limited hemorrhages, wound healing, seroma, and infection [25]. Additionally, due to limited data availability, complications related to the IOB procedure may sometimes be attributed to post-lumpectomy problems. In conclusion, both the techniques exhibit comparable surgical and treatment-related safety, with no notable differences in complication rates and toxicities. Further details can be compared in Table 2.

POB vs. IOB: Patient considerations

Patient considerations for POB vs. IOB highlight potential advantages and nuances. For older patients, particularly sensitive to the impact of anesthesia on cognitive functions, IOB stands out by avoiding a second anesthesia procedure [24, 51]. However, local anesthesia in POB could be a viable alternative for such cases. Quality of life (QOL) outcomes, when comparing multi-catheter brachytherapy APBI (POB and IOB) with standard WBRT, favors the brachytherapy approach [52-54]. On one hand, IOB's efficient process within a single-hospital minimizes logistical complexities [55];

yet, on the other hand, POB offers patients flexibility to choose a different radiotherapy center or physician. The choice between IOB and POB may also depend on institutional factors, country regulations, and health-care system preferences, impacting whether breast brachytherapy patients are treated as in-patients or out-patients. While specific hospitalization is not mandatory, post-procedure care protocols may vary based on institutional norms.

POB vs. IOB: Surgeon considerations

Independent of the technique used (POB or IOB), the implant design is normally adapted by the radiation oncologist to the surgeon’s lumpectomy technique and choice of incision. The surgical approach for IOB may vary from a perpendicular to a periareolar incision aligned with tumor location. Contemporary trends favor oncoplastic procedures that preserve cosmetic outcomes. Notably, the choice of surgical technique does not contraindicate either IOB or POB, as long as implant geometry is assured. Gimeno-Morales *et al.* [15] demonstrated the compatibility of minimal invasion surgery with IOB, underlining a crucial collaboration between surgeons and brachytherapists to achieve optimal cosmetic results. Evidence supporting POB feasibility with oncoplastic surgery was provided by Roth *et al.* [29]. To enhance cosmetics and minimize complications, a Japanese study proposed incision relocation to an inconspicuous site, mitigating wound healing issues in peri-operative APBI irradiation [56].

POB vs. IOB: Radiation oncologist considerations

Logistics play a pivotal role in the choice of breast brachytherapy. Figure 2 provides an outline of both the techniques. IOB presents notable advantages by expediting the local treatment process. Standard APBI schedules include 34 Gy in 10 fractions or 32 Gy in 8 fractions, while

very accelerated partial breast (vAPBI) schedules further trim treatment duration to 1 or 2 days (18 Gy/1 fx., 16 Gy/1 fx., 6.2 Gy/4 fx., or 7.5 Gy/3 fx.) [15, 16, 26, 57]. Such a reduction supports patient compliance, lowering infection and implant discomfort risks.

Currently, extreme hypofractionation with 5 fractions WBRT [58] is very competitive with MIB vAPBI schedule treatments [15, 16, 26, 57], because no special equipment for brachytherapy is required. Even though breast brachytherapy alleviates long waiting lists, granting patients swifter irradiation access, with potential economic benefits to healthcare systems, this is not well-described in the literature.

A significant disadvantage of IOB to highlight is the number of patients deemed ineligible for APBI post-implantation after receiving definitive pathology results. This ranges around 15-27% [25, 42, 59, 60]. Nonetheless, these patients who have already undergone IOB can receive an anticipated boost, followed by WBRT [25, 38] or catheter explantation. In contrast, POB allows a simple reconsideration of the appropriate adjuvant irradiation technique if the final pathology makes APBI unsuitable. Fortunately, in these cases, the patient would not receive brachytherapy procedure. Further information are presented in Figure 2 and Table 3.

Conclusions

Breast brachytherapy emerge as a reliable and safe technique for breast cancer treatment encompassing APBI, boost, or APBI scenarios. While long-term results are yet to establish equivalence in oncological outcomes, both POB and IOB present comparable dosimetry. The early-term toxicity is considered minimal, with no obvious toxicity differences. The choice between POB and IOB depends on the hospital dynamics, logistical considerations, and resource arrangements. These techniques can be deemed equivalent, and are suitable for

Table 3. Advantages and disadvantages of multi-catheter implant procedures

Criteria	IOB	POB
Patient comfort with regards to:		
Anesthesia	General +++	Local +
“Vectors in place” duration (days)	10 to 15	4 to 5
Infectious risk	++	+
Post-implant bleeding	+	+
Avoiding second interventional procedure	+++	+
Local treatment duration	+++	++
Brachytherapist comfort with regards to:		
Anesthesia	General	Local or general
Accuracy of identification of tumor bed and vectors placement	+++	++
Accuracy of evidence-based CTV delineation	++	+++
Quantity of breast volume irradiated (CTV vol)	+	+++
Organizational aspects with regards to:		
Pathology availability during procedure and fast pathology analysis	+++	+
Radiologist availability during procedure	+	++
Treatment modification after post-op histology	+++	+
Breast surgery team and radiation oncology team in the same hospital	+++	+
Referred patient from another hospital	Not possible	Possible

implementation in comprehensive specialized breast cancer centers.

Disclosure

The authors report no conflict of interest.

References

1. Early Breast Cancer Trialists' Collaborative Group (EBCTCG), Darby S, McGale P, Correa C et al. Effect of radiotherapy after breast-conserving surgery on 10-year recurrence and 15-year breast cancer death: meta-analysis of individual patient data for 10,801 women in 17 randomised trials. *Lancet* 2011; 378: 1707-1716.
2. Haviland JS, Owen JR, Dewar JA et al. The UK Standardisation of Breast Radiotherapy (START) trials of radiotherapy hypofractionation for treatment of early breast cancer: 10-year follow-up results of two randomised controlled trials. *Lancet Oncol* 2013; 14: 1086-1094.
3. Strnad V, Ott OJ, Hildebrandt G et al. 5-year results of accelerated partial breast irradiation using sole interstitial multicatheter brachytherapy versus whole-breast irradiation with boost after breast-conserving surgery for low-risk invasive and in-situ carcinoma of the female breast: a randomised, phase 3, non-inferiority trial. *Lancet* 2016; 387: 229-238.
4. Strnad V, Major T, Polgár C et al. ESTRO-ACROP guideline: Interstitial multi-catheter breast brachytherapy as Accelerated Partial Breast Irradiation alone or as boost – GEC-ESTRO Breast Cancer Working Group practical recommendations. *Radiother Oncol* 2018; 128: 411-420.
5. Polo A, Polgár C, Hannoun-Levi JM et al. Risk factors and state-of-the-art indications for boost irradiation in invasive breast carcinoma. *Brachytherapy* 2017; 16: 552-564.
6. Polgár C, Fodor J, Orosz Z et al. Electron and high-dose-rate brachytherapy boost in the conservative treatment of stage I-II breast cancer first results of the randomized Budapest boost trial. *Strahlenther Onkol* 2002; 178: 615-623.
7. Polgár C, Limbergen E Van, Pötter R et al. Patient selection for accelerated partial-breast irradiation (APBI) after breast-conserving surgery: Recommendations of the Groupe Européen de Curiothérapie-European Society for Therapeutic Radiology and Oncology (GEC-ESTRO) breast cancer working group based on clinical evidence (2009). *Radiother Oncol* 2010; 94: 64-73.
8. Shah C, Vicini F, Shaitelman SF et al. The American Brachytherapy Society consensus statement for accelerated partial-breast irradiation. *Brachytherapy* 2018; 17: 154-170.
9. Correa C, Harris EE, Leonardi MC et al. Accelerated Partial Breast Irradiation: Executive summary for the update of an ASTRO Evidence-Based Consensus Statement. *Pract Radiat Oncol* 2017; 7: 73-79.
10. Anderson B, Arthur D, Hannoun-Levi JM et al. Partial breast irradiation: An updated consensus statement from the American brachytherapy society. *Brachytherapy* 2022; 21: 726-747.
11. Hannoun-Levi JM, Gal J, Van Limbergen E et al. Salvage mastectomy versus second conservative treatment for second ipsilateral breast tumor event: A propensity score-matched cohort analysis of the GEC-ESTRO Breast Cancer Working Group Database. *Int J Radiat Oncol Biol Phys* 2021; 110: 452-461.
12. Lettmaier S, Kreppner S, Lotter M et al. Radiation exposure of the heart, lung and skin by radiation therapy for breast cancer: A dosimetric comparison between partial breast irradiation using multicatheter brachytherapy and whole breast teletherapy. *Radiother Oncol* 2011; 100: 189-194.
13. Mukesh M, Harris E, Jena R et al. Relationship between irradiated breast volume and late normal tissue complications: A systematic review. *Radiother Oncol* 2012; 104: 1-10.
14. Showalter SL, Grover S, Sharma S et al. Factors influencing surgical and adjuvant therapy in stage I breast cancer: a SEER 18 database analysis. *Ann Surg Oncol* 2013; 20: 1287-1294.
15. Gimeno-Morales M, Martínez-Monge R, Martínez-Regueira F et al. Four-fraction ultra-accelerated minimal breast irradiation in early breast cancer: The initial feasibility results of an institutional experience. *Brachytherapy* 2022; 21: 475-486.
16. Guinot JL, Gonzalez-Perez V, Meszaros N et al. Very accelerated partial breast irradiation Phase I-II multicenter trial (VAPBI): Feasibility and early results. *Brachytherapy* 2021; 20: 332-338.
17. Hannoun-Lévi JM, Cham Kee DL, Gal J et al. Accelerated partial breast irradiation for suitable elderly women using a single fraction of multicatheter interstitial high-dose-rate brachytherapy: Early results of the Single-Fraction Elderly Breast Irradiation (SiFEBI) Phase I/II trial. *Brachytherapy* 2018; 17: 407-414.
18. Arthur DW, Winter K, Kuske RR et al. A phase II trial of brachytherapy alone after lumpectomy for select breast cancer: Tumor control and survival outcomes of RTOG 95-17. *Int J Radiat Oncol Biol Phys* 2008; 72: 467-473.
19. Hannoun-Levi JM, Morales MG, Gal J et al. Very APBI in 1 or 2 days: Late toxicity and early oncological outcomes of the GEC-ESTRO cohort. *Int J Radiat Oncol Biol Phys* 2023; 117: S174-175.
20. Polgár C, Fodor J, Major T et al. Breast-conserving therapy with partial or whole breast irradiation: ten-year results of the Budapest randomized trial. *Radiother Oncol* 2013; 108: 197-202.
21. Strnad V, Polgár C, Ott OJ et al. Accelerated partial breast irradiation using sole interstitial multicatheter brachytherapy compared with whole-breast irradiation with boost for early breast cancer: 10-year results of a GEC-ESTRO randomised, phase 3, non-inferiority trial. *Lancet Oncol* 2023; 24: 262-272.
22. Pierquin B, Huart J, Raynal M et al. Conservative treatment for breast cancer: long-term results (15 years). *Radiother Oncol* 1991; 20: 16-23.
23. Gutiérrez C, Najjari D, Martínez E et al. The use of an interstitial boost in the conservative treatment of breast cancer: how to perform it routinely in a radiotherapy department. *J Contemp Brachytherapy* 2015; 6: 397-403.
24. Cozzi S, Laplana M, Najjari D et al. Advantages of intraoperative implant for interstitial brachytherapy for accelerated partial breast irradiation either frail patients with early-stage disease or in locally recurrent breast cancer. *J Contemp Brachytherapy* 2018; 10: 97-104.
25. Cambeiro M, Martínez-Regueira F, Rodríguez-Spiteri N et al. Multicatheter breast implant during breast conservative surgery: Novel approach to deliver accelerated partial breast irradiation. *Brachytherapy* 2016; 15: 485-494.
26. Hannoun-Lévi JM, Lam Cham Kee D, Gal J et al. Accelerated partial breast irradiation in the elderly: 5-Year results of the single fraction elderly breast irradiation (SiFEBI) phase I/II trial. *Brachytherapy* 2020; 19: 90-96.
27. Sato K, Fuchikami H, Takeda N et al. Validating the efficacy of single-stage breast-conserving therapy using multicatheter partial-breast brachytherapy based on updated ASTRO guidelines. *J Radiat Res* 2018; 59: 303-308.
28. Acea Nebrija B. "Scarless" surgery in the treatment of breast cancer. *Cirugía Española* 2010; 87: 210-217.
29. Roth AM, Kauer-Dorner D, Resch A et al. Is oncologic surgery a contraindication for accelerated partial breast radiation using the interstitial multicatheter brachytherapy method? *Brachytherapy* 2014; 13: 394-399.
30. Spillane AJ, Brennan ME. Minimal access breast surgery: a single breast incision for breast conservation surgery and sentinel lymph node biopsy. *Eur J Surg Oncol* 2009; 35: 380-386.

31. Boughey JC, Hieken TJ, Jakub JW et al. Impact of analysis of frozen-section margin on reoperation rates in women undergoing lumpectomy for breast cancer: evaluation of the National Surgical Quality Improvement Program data. *Surgery* 2014; 156: 190-197.
32. Strnad V, Hannoun-Levi JM, Guinot JL et al. Recommendations from GEC ESTRO Breast Cancer Working Group (I): Target definition and target delineation for accelerated or boost Partial Breast Irradiation using multicatheter interstitial brachytherapy after breast conserving closed cavity surgery. *Radiother Oncol* 2015; 115: 342-348.
33. Major T, Gutiérrez C, Guix B et al. Recommendations from GEC ESTRO Breast Cancer Working Group (II): Target definition and target delineation for accelerated or boost partial breast irradiation using multicatheter interstitial brachytherapy after breast conserving open cavity surgery. *Radiother Oncol* 2016; 118: 199-204.
34. Major T, Polgar C. Treatment planning for multicatheter interstitial brachytherapy of breast cancer – from Paris system to anatomy-based inverse planning. *J Contemp Brachytherapy* 2017; 9: 89-98.
35. Pierquin B, Dutreix A, Paine CH et al. The Paris system in interstitial radiation therapy. *Acta Radiol Oncol Radiat Ther Phys Biol* 1978; 17: 33-48.
36. Aristei C, Lancellotta V, Piergentini M et al. Individualized 3D-printed templates for high-dose-rate interstitial multicatheter brachytherapy in patients with breast cancer. *Brachytherapy* 2019; 18: 57-62.
37. Poulin E, Gardi L, Fenster A et al. Towards real-time 3D ultrasound planning and personalized 3D printing for breast HDR brachytherapy treatment. *Radiother Oncol* 2015; 114: 335-338.
38. Morales M, Martinez-Regueira F, Rodriguez-Spiteri N et al. Minimally invasive tumor bed implant (MITBI) and peri-operative high-dose-rate brachytherapy (PHDRBT) for accelerated minimal breast irradiation (AMBI) or anticipated boost (A-PHDRBT-boost) in breast-conserving surgery for ductal carcinoma in situ. *J Contemp Brachytherapy* 2020; 12: 521-532.
39. Sato K, Shimo T, Fuchikami H et al. Catheter-based delineation of lumpectomy cavity for accurate target definition in partial-breast irradiation with multicatheter interstitial brachytherapy. *J Contemp Brachytherapy* 2019; 11: 108-115.
40. Kinj R, Chand ME, Gal J et al. Single fraction of accelerated partial breast irradiation in the elderly: Early clinical outcome. *Radiat Oncol* 2018; 13: 174.
41. Polgár C, Major T, Takácsi-Nagy Z et al. Breast-conserving surgery followed by partial or whole breast irradiation: Twenty-year results of a phase 3 clinical study. *Int J Radiat Oncol Biol Phys* 2021; 109: 998-1006.
42. Sato K, Fuchikami H, Takeda N et al. Efficacy of single-plane implant technique in partial breast brachytherapy in small-breasted patients. *Int J Radiat Oncol Biol Phys* 2020; 106: 830-837.
43. Herein A, Stelczer G, Pesznyák C et al. Multicatheter interstitial brachytherapy versus stereotactic radiotherapy with CyberKnife for accelerated partial breast irradiation: a comparative treatment planning study with respect to dosimetry of organs at risk. *Radiol Oncol* 2021; 55: 229-239.
44. Livi L, Meattini I, Marrazzo L et al. Accelerated partial breast irradiation using intensity-modulated radiotherapy versus whole breast irradiation: 5-year survival analysis of a phase 3 randomised controlled trial. *Eur J Cancer* 2015; 51: 451-463.
45. Meattini I, Marrazzo L, Saieva C et al. Accelerated partial-breast irradiation compared with whole-breast irradiation for early breast cancer: Long-term results of the randomized phase III APBI-IMRT-Florence trial. *J Clin Oncol* 2020; 38: 4175-4183.
46. Vicini FA, Cecchini RS, White JR et al. Long-term primary results of accelerated partial breast irradiation after breast-conserving surgery for early-stage breast cancer: a randomised, phase 3, equivalence trial. *Lancet* 2019; 394: 2155-2164.
47. Sato K, Fuchikami H, Kato M et al. Efficacy of single-stage breast-conserving treatment using multicatheter partial breast brachytherapy evaluated by GEC-ESTRO phase 3 trial. *J Contemp Brachytherapy* 2017; 9: 424-430.
48. Ott OJ, Strnad V, Hildebrandt G et al. GEC-ESTRO multicenter phase 3-trial: Accelerated partial breast irradiation with interstitial multicatheter brachytherapy versus external beam whole breast irradiation: Early toxicity and patient compliance. *Radiother Oncol* 2016; 120: 119-123.
49. Hannoun-Levi JM, Resch A, Gal J et al. Accelerated partial breast irradiation with interstitial brachytherapy as second conservative treatment for ipsilateral breast tumour recurrence: Multicentric study of the GEC-ESTRO Breast Cancer Working Group. *Radiother Oncol* 2013; 108: 226-231.
50. Polgár C, Fodor J, Major T et al. Breast-conserving therapy with partial or whole breast irradiation: Ten-year results of the Budapest randomized trial. *Radiother Oncol* 2013; 108: 197-202.
51. Moller JT, Cluitmans P, Rasmussen LS et al. Long-term post-operative cognitive dysfunction in the elderly: ISPOCD1 study. *Lancet* 1998; 351: 857-861.
52. Wadasadawala T, Maitre P, Sinha S et al. Patient-reported quality of life with interstitial partial breast brachytherapy and external beam whole breast radiotherapy: a comparison using propensity-score matching. *J Contemp Brachytherapy* 2021; 13: 387-394.
53. Perrucci E, Lancellotta V, Bini V et al. Quality of life and cosmesis after breast cancer: whole breast radiotherapy vs partial breast high-dose-rate brachytherapy. *Tumori* 2015; 101: 161-167.
54. Boulahssass R, Chand ME, Gal J et al. Quality of life and Comprehensive Geriatric Assessment (CGA) in older adults receiving accelerated partial breast irradiation (APBI) using a single fraction of multi-catheter interstitial high-dose rate brachytherapy (MIB). The SiFEBI phase I/II trial. *J Geriatr Oncol* 2021; 12: 1085-1091.
55. Abbott AM, Habermann EB, Tuttle TM. Trends in the use of implantable accelerated partial breast irradiation therapy for early stage breast cancer in the United States. *Cancer* 2011; 117: 3305-3310.
56. Sato K, Fuchikami H, Takeda N et al. Moving incision for covert breast-conserving surgery may prevent early wound complications in brachytherapy-based partial-breast irradiation. *Brachytherapy* 2019; 18: 645-650.
57. Latorre JA, Galdós P, Buznego LA et al. Accelerated partial breast irradiation in a single 18 Gy fraction with high-dose-rate brachytherapy: preliminary results. *J Contemp Brachytherapy* 2018; 10: 58-63.
58. Murray Brunt A, Haviland JS, Wheatley DA et al. Hypofractionated breast radiotherapy for 1 week versus 3 weeks (FAST-Forward): 5-year efficacy and late normal tissue effects results from a multicentre, non-inferiority, randomised, phase 3 trial. *Lancet* 2020; 6736: 1-14.
59. Vaidya JS, Wenz F, Bulsara M et al. Risk-adapted targeted intraoperative radiotherapy versus whole-breast radiotherapy for breast cancer: 5-year results for local control and overall survival from the TARGIT – A randomised trial. *Lancet* 2014; 383: 603-613.
60. Sato K, Mizuno Y, Kato M et al. Intraoperative open-cavity implant for accelerated partial breast irradiation using high-dose rate multicatheter brachytherapy in Japanese breast cancer patients: A single-institution registry study. *J Cancer Ther* 2012; 3: 822-830.